A Hidden Concern in Ocular Rosacea

Sandra Lora Cremers, MD, FACS

March 2013

Sensing that he was about to doze off, the air bag on Wade's computer rapidly deployed.





Ro

Borin

amoro

Not



Objectives:

1. Describe Epidemiology, Diagnosis, Pathophysiology, and Treatment of Rosacea and Ocular Rosacea

2. Discuss Recent Research Finding of Rosacea and Ocular Rosacea

3. Discuss Ocular Rosacea's Relationship to other Angiogenesis Based Diseases

Outline:

1. Case Presentations
2. Diagnosis and Details
3. Observations & Collaborations
4. A Hidden Concern

1. Case Presentations

Case Presentation:

79 yo white male presents complaining of "poor vision in right eye after cataract surgery. Worse than before the surgery"

Case Presentation:

BCVA: 20/50 OD, 20/30 OS

External exam:



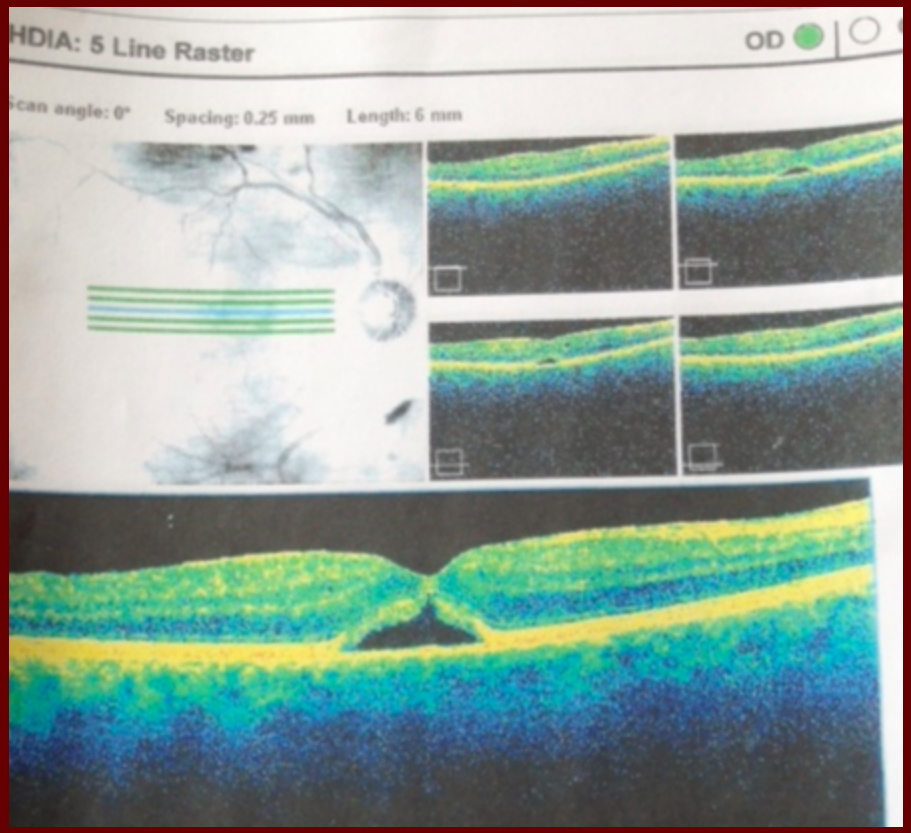
HDIA: 5 Line Raster
OD
Scan angle: 0°
Spacing: 0.25 mm
Length: 6 mm

Macular anomaly - Ocular Rosacea?

Forum rules
IMPORTANT: Click "Subscribe topic" on the yellow bar at the bottom of your topic page to receive email notification of reply.

POSTREPLY Search this topic... Search

Macular anomaly - Ocular Rosacea?

by [redacted]

Hello,
My name is [redacted]
I am a 79 year old white male.

Some 5 or so years ago, I began to have the first signs of Rosacea on my nose, constant itching with minor visual blemishes. I had not heard of the name 'Rosacea' at the time.

My [redacted] physician advised to use an over the counter itch cream, but did not comment on the possibility that I might be in the early stages of Rosacea.

[redacted]

By now, the nose Rosacea had progressed to the visual stage with whelps and some enlargement of the nose.

I had cataracts, one required removal soon, and I arranged to have the surgery.

The Ophthalmologist apparently took no notice, nor precautions for the possible Ocular Rosacea being present, and performed the surgery.

After surgery, I had (and still have) a small macular anomaly which causes anything in the dead center of my vision to be 'scrambled', the Peripheral vision is good, and the area of the anomaly is about half an inch at arms length, increasing with distance.

This almost completely destroys depth perception.

I have seen 4 Ophthalmologist – Optometrist, none of which has identified the problem, but have recently prescribed treatment consistent with Ocular Rosacia. Hot eye compresses, artificial tears, and a topical Erythromycin Ophthalmic Ointment to the eye margins.

My questions are:

Did the presence of Ocular Rosacea in the eye region infect the eye during cataract surgery? (theories accepted) especially since the surgeon did nothing prior to cataract removal to cleanse the eye, and no antibiotics were administered before or after. After the surgery, and the anomaly was discovered, I was treated for edema, although there was no evidence of edema in either eye. (Timed series of photographs, using an intravenous dose of Angiofluor, a derivative of Fluorescein)?

The second Ophthalmologist did (laser?) scans of both eyes, the right eye that has the macular problem showed what he described as 'an infection'.

For the following year, I had eye scans every 2 to 4 months...the anomaly was treated with Nevanac, an antibiotic eye drop, (nepafenac ophthalmic suspension) 0.1%.

The doctor did advise this eye drop was not designed for this type of infection, but was the only medication he knew of that could help.

Over the course of one year, the anomaly did subside, but stopped short of complete healing.

Ultimate Diagnosis:

Unhappy patient because he perceived a missed diagnosis of ocular rosacea as the reason for less than expected vision after cataract surgery.

A Brief Historical Perspective



Young Rembrandt

Older Rembrandt

2. Diagnosis and Details

A Definition of Rosacea

Rosacea is a multifactorial, hyper-reactivity, vascular and neural based disease with a broad range of facial and manifestations where normal vasodilation is greater and more persistent and involves an autoimmune component where microscopic amounts of extravasated plasma induce localized dermal inflammation where repeated external triggers lead vasodilation, telangiectasias, redness with eventual fibrosis and hypertrophic scarring of the dermis.

Subtypes of ROSACEA

Subtype 1:
FACIAL REDNESS
(erythematotelangiectatic rosacea) Flushing and persistent redness. Visible blood vessels may also appear.

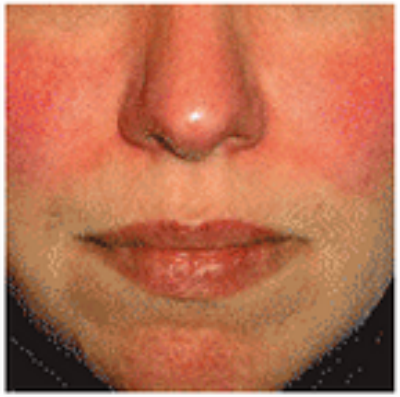

Subtype 2:
BUMPS AND PIMPLES
(papulopustular rosacea) Persistent facial redness with bumps or pimples. Often seen following or with subtype 1.

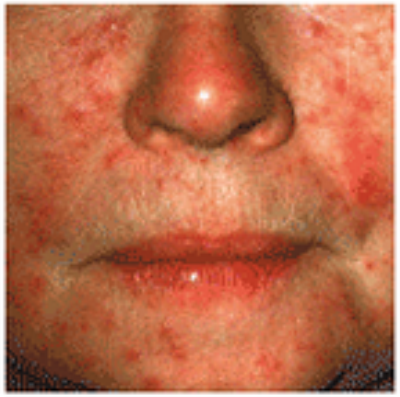

Subtype 3:
SKIN THICKENING
(phymatous rosacea) Skin thickening and enlargement, usually around the nose.

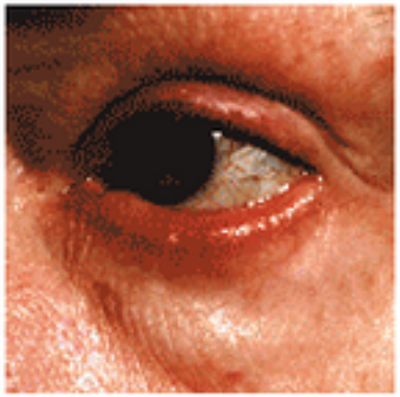

Subtype 4:
EYE IRRITATION
(ocular rosacea) Watery or bloodshot appearance, irritation, burning or stinging.

Differential Diagnosis of Rosacea

Disease	Similarities	Differences
Acne vulgaris	• Papules, pustules, erythema	• Comedones • Earlier onset • Not limited to central third of face • No telangiectasias or flushing
Steroid rosacea	• Erythema, papules, pustules, telangiectasias • Central third of face	• Related to topical application of corticosteroids, tacrolimus (Protopic, Astellas/Fujisawa), and pimecrolimus (Elidel, Novartis)
Seborrheic dermatitis	• Blepharitis • Erythema	• Scaling, eczematous changes • Paranasal, nasolabial, extrafacial distribution
Perioral dermatitis	• Erythema, papules	• Perioral distribution • Smaller lesions • No telangiectasia, flushing, or blushing
Contact dermatitis	• Erythema, papules, pustules • Burning, stinging	• Follows size and shape of causal agent • Scaling • Spongiosis and parakeratosis on histology
Photodermatitis	• Erythema, papules, plaques	• Seasonal • Usually extrafacial
Lupus	• Erythema	• Malar distribution • Photosensitivity

FDA-Approved Topical and Oral Therapies for Rosacea

Topical Antibiotics	Non-antibiotics	Oral Antibiotics
Metronidazole 0.25%, 0.75%, 1% cream, gel, lotion (e.g., MetroCream, MetroGel)	Azelaic acid 15% gel (Azelex)	Doxycycline, USP (Oracea Capsules) 40 mg once daily (30-mg immediate-release and 10-mg delayed-release beads)
	Sodium sulfacetamide 10% and sulfur 5% combination, lotion, cream, pledgets, short-contact preparation, cleanser (Sulfacet)	
	Sodium sulfacetamide 10% lotion	
	Sodium sulfacetamide 10%, sulfur 5%, sunblock lotion	

Non–FDA-Approved Oral Treatment of Rosacea

Standard but Non-approved Oral Antibiotics	Useful but Less Commonly Used Oral Antibiotics	Oral Antibiotics Reported but Not in Common Clinical Use	Oral Treatment of Flushing	Non-antibiotic Oral Treatment
Tetracycline 500 mg b.i.d.	Azithromycin 250 mg t.i.w. (Zithromax)	Penicillin 2.4 million units q.d.	Oral contraceptives (Ovosiston)	Ivermectin 250 μ/kg q.w. (Stromectol)
Doxycycline 50–100 mg b.i.d.	Clarithromycin 250–500 mg b.i.d.–q.d. (Biaxin)	Erythromycin 250–500 mg b.i.d.–q.i.d. (Akne-Mycin)	Psychiatric medications • Amitriptyline 25 mg q.d. (Elavil) • Clonidine 0.1 mg q.d.	Isotretinoin 0.15–2 mg/kg q.d. (Accutane)

Non–FDA-Approved Topical Treatment of Rosacea

Topical Antibiotics	Topical Treatment Reportedly Used Effectively	Topical Treatments Theoretically Useful But Not Used Clinically
Clindamycin 1% lotion, gel, solution, pledget (Cleocin)	Azelaic acid 20% cream (Azelex)	Crotamiton 10% q.d.–t.i.d. (Eurax)
Erythromycin 2% solution, ointment, pledget (Akne-Mycin)	Permethrin cream 5% q.d.–q.w. (Nix)	Lindane 1% cream q.d.
Benzoyl peroxide 5%/clindamycin 1% (BenzaClin, Benzamycin)	Adapalene cream, gel (Differin)	Benzoyl peroxide, gel, wash q.d.–b.i.d. (Benzac, Benzagel)
Sunscreen with dimethicone or cyclomethicone	Tacrolimus ointment q.d.–b.i.d. (Protopic)	Retinaldehyde 0.05% cream
Benzoyl peroxide 5% and erythromycin 1% combination cream, pledget	Pimecrolimus 1% Cream q.d.–b.i.d. (Elidel)	Tretinoin cream, gel (Retin-A)

What is Ocular Rosacea and How do you make the Diagnosis?

Epidemiology of Ocular Rosacea:

1. In 3-58% of patients with Rosacea
2. M=F
3. European descent more common
4. Starts in 20's and often worsens with age
5. Can be seen in kids

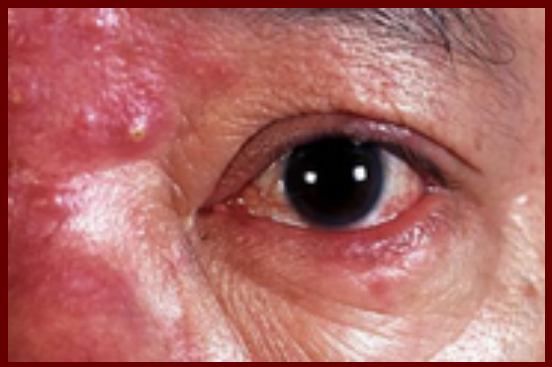

Spontaneous Corneal Perforation in Ocular Rosacea

Middle East Afr J Ophthalmol. 2010 Apr-Jun; 17(2): 186–188

Symptoms:

1. Burning
2. Foreign body sensation
3. Dry eye
4. Tearing (reflex)
5. Eye redness
6. Mattering of eyelids

Signs:

1. Blepharitis & MGD
2. Lid margin telangiectasia
3. Conjunctivitis
4. Recurrent chalazia
5. Corneal pannus
6. SPK
7. Episcleritis, Scleritis (not common)
8. Interstitial keratitis & [illegible] ne scarring

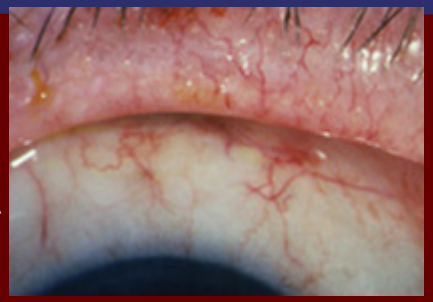

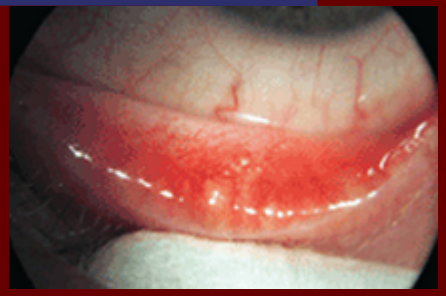

Signs:

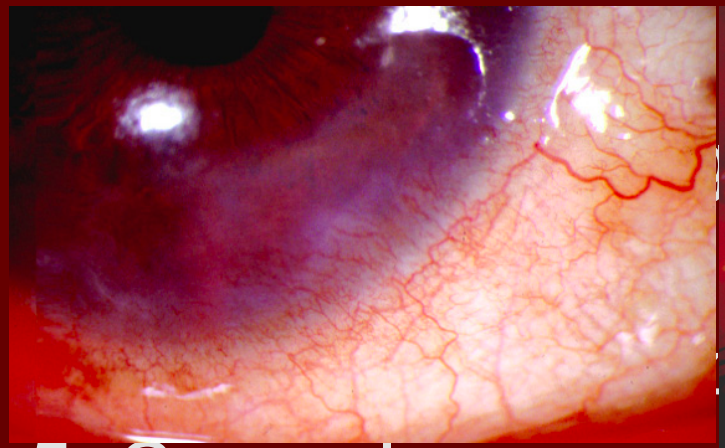
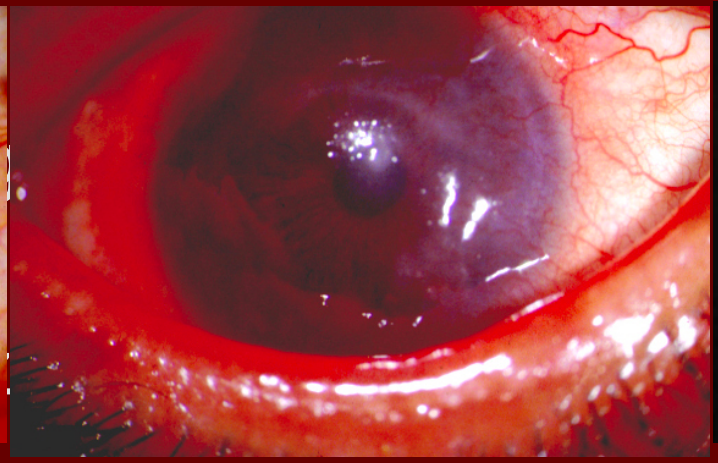
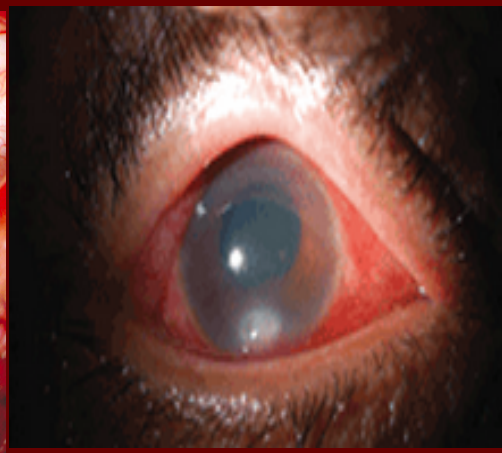

5. Corneal pannus
6. SPK
7. Episcleritis, Scleritis (not common)
8. Interstitial keratitis & residual corneal scarring

Pathophysiology

Many Theories of Ocular Rosacea

Ingested Agents

Climatic Exposures

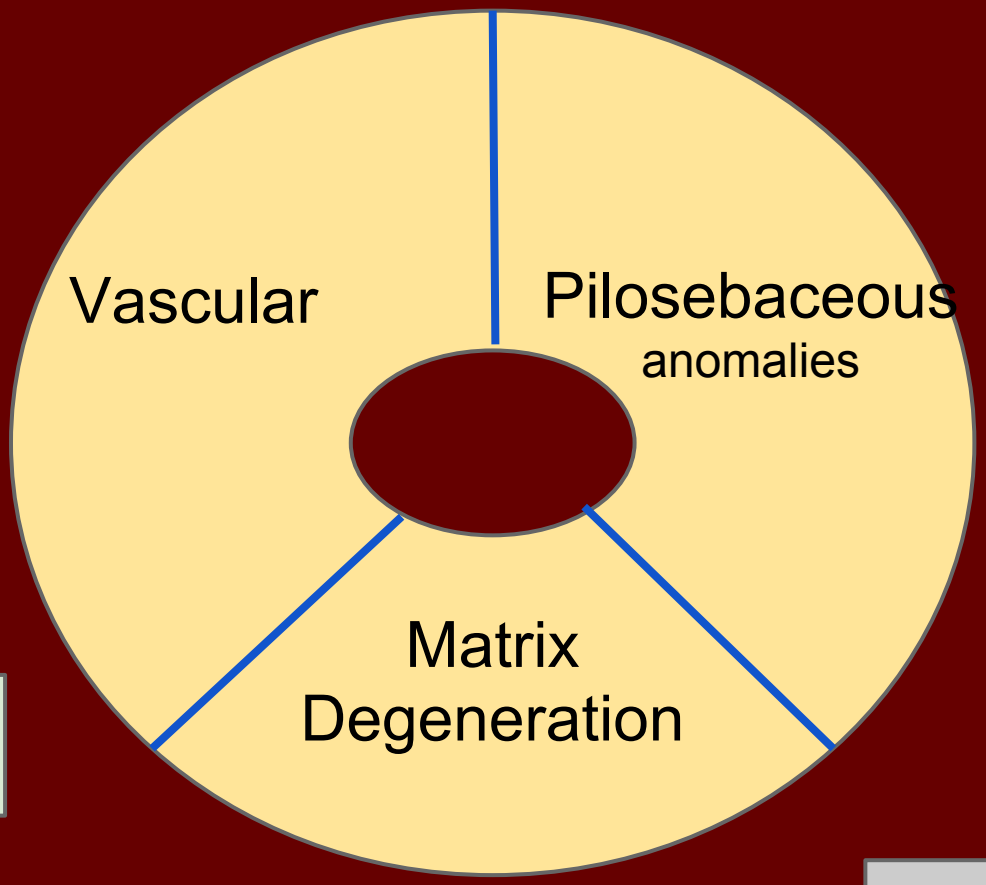

Chemicals

Microbial

Demodex

Bacillus
oleronius

Many Theories of Ocular Rosacea

- Demodex folliculorum mites: Bacillus oleronius bacteria within
- Increased sulfated O-glycans in tear film

TIME Health & Family

SUBSCRIBE | Magazine | Video | LIFE | Person of the Year

NEWSFEED | U.S. | POLITICS | WORLD | BUSINESS | TECH | HEALTH | SCIENCE | ENTERTAIN

Home | Medicine | Diet & Fitness | Family & Parenting | Love & Relationships | Mental Health | Policy & Industry

360 Savings
• JOIN 7.5 MILLION OTHER SUPER SAVERS
• MAKE A SMALL DEPOSIT TO GET STARTED

RESEARCH

Rosacea: Caused by Mite Poop in Your Facial Pores?

By Alexandra Sifferlin | Sept. 04, 2012 | 5 Comments

Share | Like 208 | Tweet 88 | +1 0 | Share 1

In truly disgusting news, rosacea — a fairly common acne-like condition characterized by red, inflamed skin — may be caused by tiny bugs living in the pores of your face, reports a researcher at National University of Ireland.

The little eight-legged mites called *Demodex*, which are related to spiders, are apparently drawn to the hair follicles of eyebrows and eyelashes and to the oily pores on your nose, forehead and cheeks. They feed on the oil, or sebum, in your skin, and

DEMODEX

Complications of Ocular Rosacea

1. Chronic Dry Eye
2. Corneal Vascularization
3. 2nd Bacterial Infections
4. Perforation
5. Increased graft failure after PK

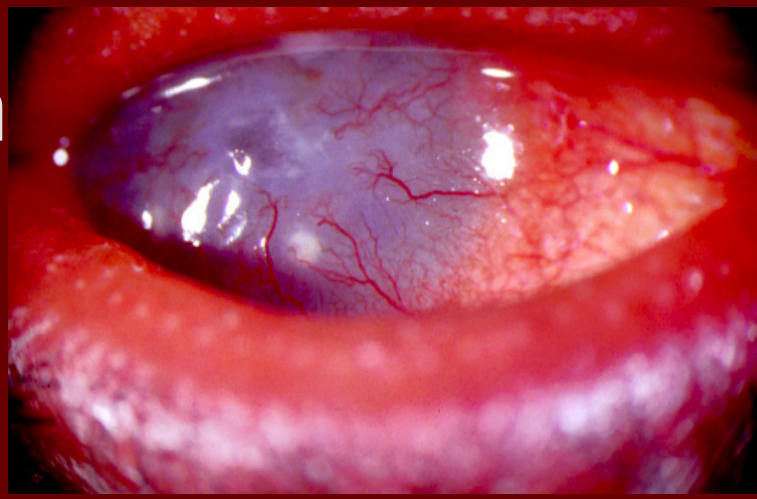

Complications of Ocular Rosacea

Increased Graft Rejection in PK patients

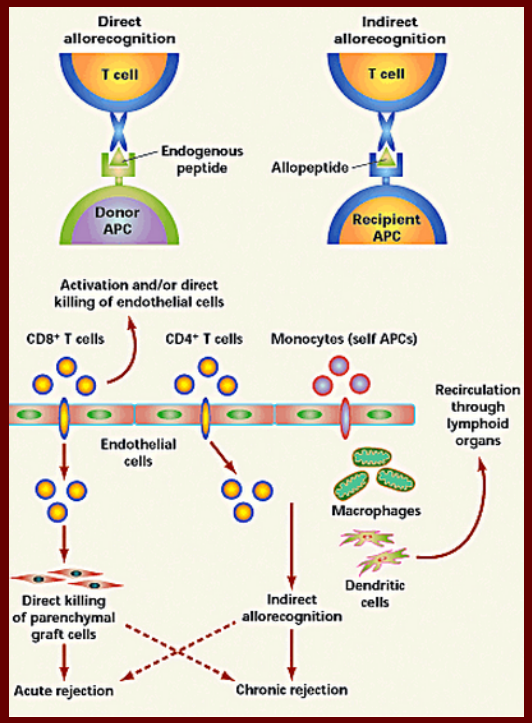

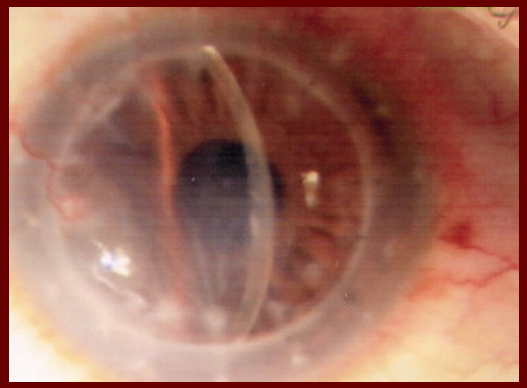

Treatments

Usual Treatments of Ocular Rosacea

1. Lid hygiene: Warm Compresses Baby shampoo scrubs
2. Artificial tears, nonpreserved
3. Antibiotics po: doxycycline, tetracycline, clarithromycin, metronidazole; Erythromycin for kids
4. Erythromycin ointment
5. Topical steroids
6. Restasis: Topical cyclosporine A b.i.d. x 3 mo

Newer Ocular Rosacea Treatments:

1. Intense Pulse Light Therapy (IPL)

3. LipiFlow

4. Intraductal MG Probing, Maskin

Doxycycline Risks:

HealthBoards
HEALTH MESSAGE BOARDS

Search HealthBoards | Search

Home | Health Centers | Message Boards | Videos | Drug Talk | Blogs | SIGN UP | LOGIN

FAQ | Posting Policy | Advanced Search | Find A Board | Site Map

06-15-2005, 11:07 AM

RetiredDirector
Senior Veteran
(male)

Join Date: Oct 2001
Location: Washington
Posts: 1,358

Re: Clostridium difficile, c.diff intestinal infection anyone?

I too, was on antibiotics for a long time. I was on Doxycycline and never dreamed I'd have any problems like C-Diff, but I did. Things were really getting bad and I was to the point where I would have "accidents" at night while asleep and it even happened twice in public. Fortunately they were small and I was able to leave and go home before it was noticed by anyone.

I had gone to the doctor and had a colonoscopy when it was diagnoised from a stool culture. I spent two weeks on Vancocin, 250 mg BID, but now am on Vancocin, 125 mg one every other day. I am able to tell a huge difference already and I think when I finish the medication it should be cleared up completely. It will be just in time for our vacation trip to Hawaii.

Welcome to the boards Greenmyst, I hope things go better for you from now on and your symptoms are taken care with the medication.

Director

Prevention

Usual Prevention:

- Avoid foods, drinks, and situations that trigger outbreaks like sun
- Hat, sunglasses
- increase Omega 3s intake

Ingested/Iatrogenic	Environmental
Foods and drinks	***Temperature***
Cheese (except cottage)	Sauna heat
Chocolate	Overheating
Spicy food	Sun lamp
Soy sauce	Humidity
Vanilla	Hot baths
Dairy products	***Weather***
Liver	Sun
Beverages	Heat
Red wine	Strong wind
Hot drinks	Cold
Alcohol (beer, bourbon, gin, vodka)	***Emotion***
	Anger
Drugs	Stress
Niacin	Rage
Nitroglycerin	Embarrassment
Tobacco	***Activity***
Topical agents	Exercise
Topical corticosteroids	Menopause
Retinoids	Caffeine withdrawal
Cosmetics (sometimes)	Chronic cough
Acetones	Straining
Alcohol	

4. A Hidden Concern

Years of Observations of Ocular Rosacea

1. If also had diabetes, tended to develop proliferative diabetic retinopathy

2. If they also had age related macular degeneration (ARMD), tended to develop wet ARMD

3. If they had a corneal transplant, they would tend to have a rejection more often.

A Chance Encounter at Grand Rounds

Who is this man?

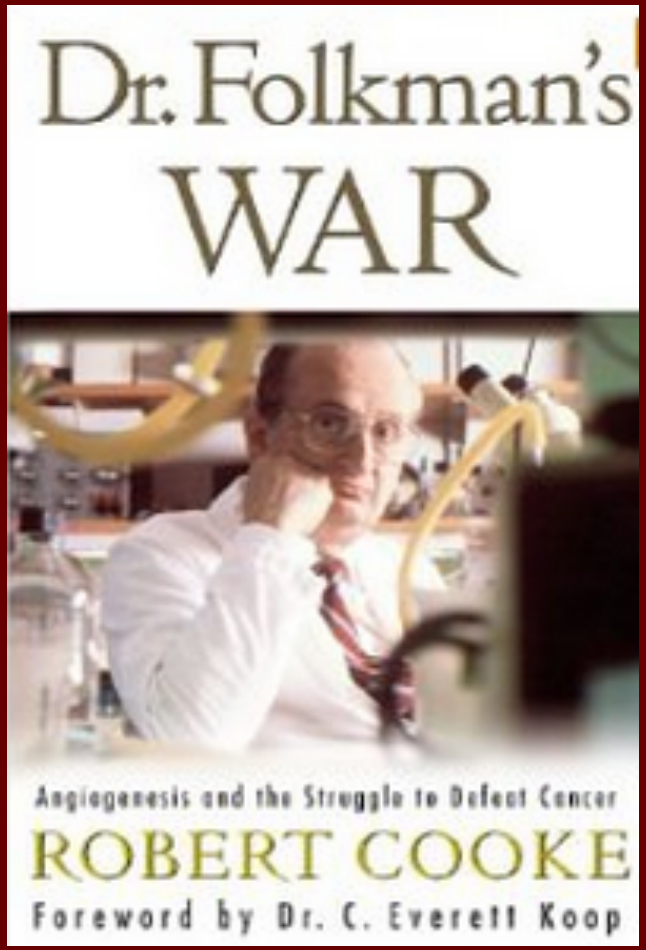
Dr. Folkman's
WAR
Angiogenesis and the Struggle to Defeat Cancer
ROBERT COOKE
Foreword by Dr. C. Everett Koop

ISOLATION OF A TUMOR FACTOR RESPONSIBLE FOR ANGIOGENESIS*

By JUDAH FOLKMAN, M.D., EZIO MERLER, Ph.D., CHARLES ABERNATHY, M.D., and GRETCHEN WILLIAMS

(From the Departments of Surgery and Pediatrics, Children's Hospital Medical Center and Harvard Medical School, Boston, Massachusetts 02115)

(Received for publication 15 September 1970)

Algire suggested that an attribute of tumor cells is their capacity to elicit continuously the growth of new capillary endothelium in vivo (1). Subsequently, Greene observed that tiny tumors implanted for more than a year in the anterior chamber of the guinea pig eye would not grow because they could not become vascularized (2). When these tumors were reimplanted in the muscle of a rabbit where they could become vascularized, they grew to a large size.

The growth of tumors which have been implanted in any one of several different organs and maintained by a long-term perfusion stops when the tumor reaches a diameter of 3–4 mm (3). Further growth of tumor tissue in in vitro organ cultures cannot be sustained without neovascularization of the tumor (4). Neovascularization does not require direct contact by tumor cells since vessels have been elicited from the hamster cheek pouch by tumors contained in a Millipore filter (5, 6). Similar outgrowth of new blood vessels was observed by us when Millipore chambers containing cells of B-16 melanoma or Walker carcinoma were implanted into the dorsal air sac of rats. In the present communication, the isolation of a soluble factor from human and animal neoplasms which is mitogenic for capillary endothelium is described. This factor induces growth of new capillaries, and it is proposed that it is responsible for tumor angiogenesis.

Materials and Methods

Isolation of Tumor–Angiogenesis, Factor (TAF).[1]—Walker 256 ascites tumor was harvested from 21-day old Sprague-Dawley rats which had been injected with 2×10^6 tumor cells 4–5 days previously. About 5 ml of bloody ascites were removed aseptically from the exposed

* This investigation was supported by U. S. Public Health Service Grants CA 08185-5-05, AI-05877, and AI-00366, and by a Grant from the Merck Company, and a gift from the Given Foundation.

A preliminary report of portions of this work has been presented (*J. Clin. Invest.* 1970. **49:** 30a. [Abstr.]).

[1] *Abbreviation used in this paper:* TAF, tumor–angiogenesis factor.

doi:10.1038/nature08062 nature

Nature. 2009 Jun 25;459(7250):1126-30. doi: 10.1038/nature08062.

LETTERS

Down's syndrome suppression of tumour growth and the role of the calcineurin inhibitor DSCR1

Kwan-Hyuck Baek[1]*, Alexander Zaslavsky[1]*, Ryan C. Lynch[1]*, Carmella Britt[1], Yoshiaki Okada[2], Richard J. Siarey[3], M. William Lensch[4], In-Hyun Park[4], Sam S. Yoon[5], Takashi Minami[6], Julie R. Korenberg[7], Judah Folkman[1], George Q. Daley[4], William C. Aird[2], Zygmunt Galdzicki[3] & Sandra Ryeom[1]

The incidence of many cancer types is significantly reduced in individuals with Down's syndrome[1–4], and it is thought that this broad cancer protection is conferred by the increased expression of one or more of the 231 supernumerary genes on the extra copy of chromosome 21. One such gene is Down's syndrome candidate region-1 (*DSCR1*, also known as *RCAN1*), which encodes a protein that suppresses vascular endothelial growth factor (VEGF)-mediated angiogenic signalling by the calcineurin pathway[5–10]. Here we show that DSCR1 is increased in Down's syndrome tissues and in a mouse model of Down's syndrome. Furthermore, we show that the modest increase in expression afforded by a single extra transgenic copy of *Dscr1* is sufficient to confer significant suppression of tumour growth in mice, and that such resistance is a consequence of a deficit in tumour angiogenesis arising from suppression of the calcineurin pathway. We also provide evidence that attenuation of calcineurin activity by DSCR1, together with another chromosome 21 gene *Dyrk1a*, may be sufficient to markedly diminish angiogenesis. These data provide a mechanism for the reduced cancer incidence in Down's syndrome and identify the calcineurin signalling pathway, and its regulators DSCR1 and DYRK1A, as potential therapeutic targets in cancers arising in all individuals.

Down's syndrome is the most common genetic cause of mental retardation in humans, occurring in 1 out of 700 live births. Epidemiological studies suggest that although individuals with Down's syndrome have an increased risk of leukaemia, they have a considerably reduced incidence of most solid tumours[1–4]. In the largest study to date involving 17,800 Down's syndrome individuals, the mortality from cancers was <10% of expected[4]. Such data indicate that one or more of the 231 trisomic genes on chromosome 21 is responsible for protecting these individuals against cancer. Of note, Down's syndrome individuals also have a reduced incidence of other angiogenesis-related diseases, such as diabetic retinopathy[11] and atherosclerosis[12], suggesting that cancer protection in the Down's syndrome population may be due, in part, to angiogenesis suppression.

embryos, as well as increased expression of DSCR1 fetal isoforms[5], compared with those from age-matched control fetuses (Fig. 1a). Substantial synteny exists in gene identity and order between much of human chromosome 21 and the mouse[13]. The Ts65Dn mouse model of Down's syndrome is trisomic for 104 of the 231 genes on human chromosome 21, including DSCR1 (ref. 14) (Supplementary Fig. 1a). We probed tissues from Ts65Dn mice to ascertain whether DSCR1 was also upregulated in the Ts65Dn mouse and found a 1.7-fold increase in DSCR1 protein expression compared with diploid littermates (Supplementary Fig. 1b). Thus, DSCR1 expression in Ts65Dn mice is increased in an analogous fashion to DSCR1 expression in Down's syndrome fetal tissues.

We proposed that the inhibition of tumorigenesis in the Down's syndrome population may be partially due to the suppression of tumour angiogenesis, thus predicting that the inhibitory effect of *DSCR1* trisomy on tumour growth occurs within the host tumour microenvironment. To establish whether the Ts65Dn Down's syndrome mouse, like Down's syndrome individuals, exhibits generalized protection from cancers, we assayed the growth of two transplantable tumour models: Lewis lung carcinoma and B16F10 melanoma cells. We observed considerable growth suppression of both Lewis lung and B16F10 tumour cells in Ts65Dn mice relative to littermate controls (Fig. 1b), correlating with a significant decrease in microvessel density (Fig. 1c). Endothelial cells isolated from Ts65Dn mice demonstrated upregulation of *Dscr1* mRNA in contrast to diploid littermates (Supplementary Fig. 1c) and were notably less responsive to VEGF-mediated proliferation *in vitro* (Supplementary Fig. 1d), further implicating an angiogenic defect in these mice. Thus, trisomy for orthologues of half the genes on human chromosome 21 was sufficient to slow ectopic tumour growth.

To validate that the compromised angiogenesis we observed in murine models of Down's syndrome extended to human cells carrying trisomy 21, we compared microvessel density in teratomas derived from Down's syndrome induced pluripotent stem (iPS) cells versus those from cytogenetically normal iPS cells from a healthy volunteer[15]

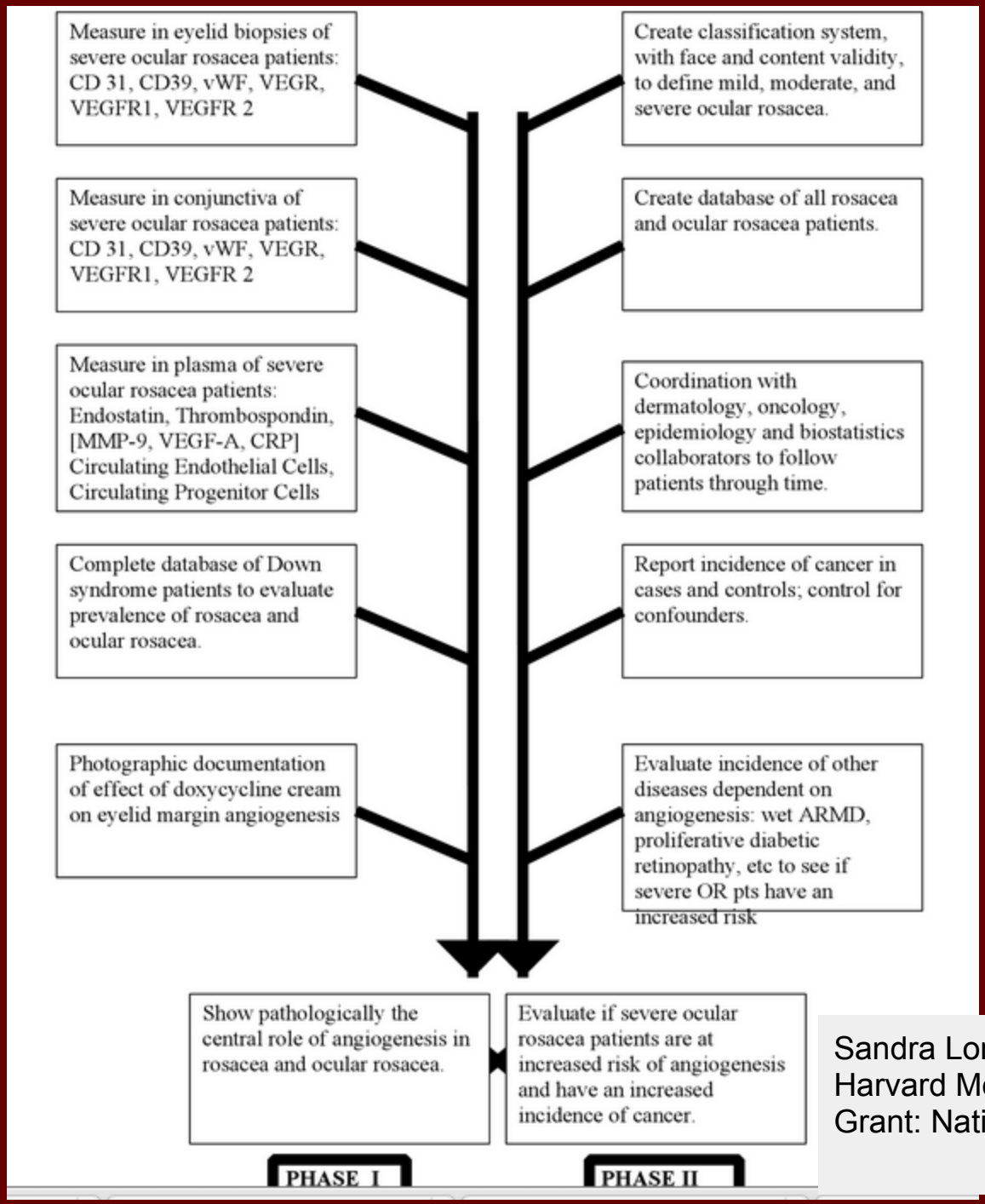

Sandra Lora Cremers, MD, FACS
Harvard Medical School
Grant: National Rosacea Society

SEVERITY CRITERIA OF OCULAR ROSACEA (SCOR): A Practical Method to Evaluate the Severity of Rosacea

Jae Yong Kim, MD, PhD,[1,2] Ednan Ahmed, MD,[1] Neetu Brar, MD,[1] Andrea Lora, MD,[3] Sandra Lora Cremers, MD, FACS.[1]

[1]Massachusetts Eye and Ear Infirmary, Harvard Medical School, Boston, MA

[2]Department of Ophthalmology, University of Ulsan College of Medicine, Asan Medical Center, Seoul, Republic of Korea. [3]Bascom Palmer Eye Institute, University of Miami, School of Medicine, Miami, FL

Material has been previously presented at the American Academy of Ophthalmology Annual Meeting, November, 2006.

None of the authors have any financial interest in any products or materials in this study.

Financial support

This study was supported by grants from the Research to Prevent Blindness, the Massachusetts Lions Foundation, the Norman Knight Ophthalmology Fund, the Harvard 50th Anniversary Scholars Grant, and a grant (2012-464) from the Asan Institute for Life Sciences, Seoul, Korea.

Corresponding Author:

Sandra Lora Cremers, MD, FACS

Harvard Medical School, The Massachusetts Eye and Ear Infirmary

243 Charles Street, Boston, MA 02114

SEVERITY CRITERIA OF OCULAR ROSACEA (SCOR):

Dear Patient: Please **CHECK-off** boxes in the top portion of the sheet **(Questions 1-14)** according to question: **"How often do you have these symptoms based on % of time?"**

Patient Reported Symptoms & Signs: Patient or MD can complete this section.	Absent= 0 **0% of wk** **Never**	Mild= 1 **Rarely**	Moderate= 2 **50% of week** **Sometimes**	Severe= 3 **Often**	Very Severe= 4 **100% of week** **All the Time**
1. Itchy eyes					
2. Dryness of eyes					
3. Tearing/Discharge					
4. Foreign Body Sensation					
5. Burning/stinging of eyes					
6. Light sensitivity/photophobia					
7. Swelling					
8. Crusting of eyelids					
9. History or current chalazion/stye					(Recurrent=4 points)
10. Loss of lashes					
11. Eye pain					
12. Blurred vision					
13. Redness of eyes/eyelid					
14. Facial/nose/cheek redness					
Ocular Signs: Eye MD to fill in	**Absent= 0**	**Mild= 1**	**Moderate= 2**	**Severe= 3**	**Very Severe= 4**

Results: Patient 3, CD 31+

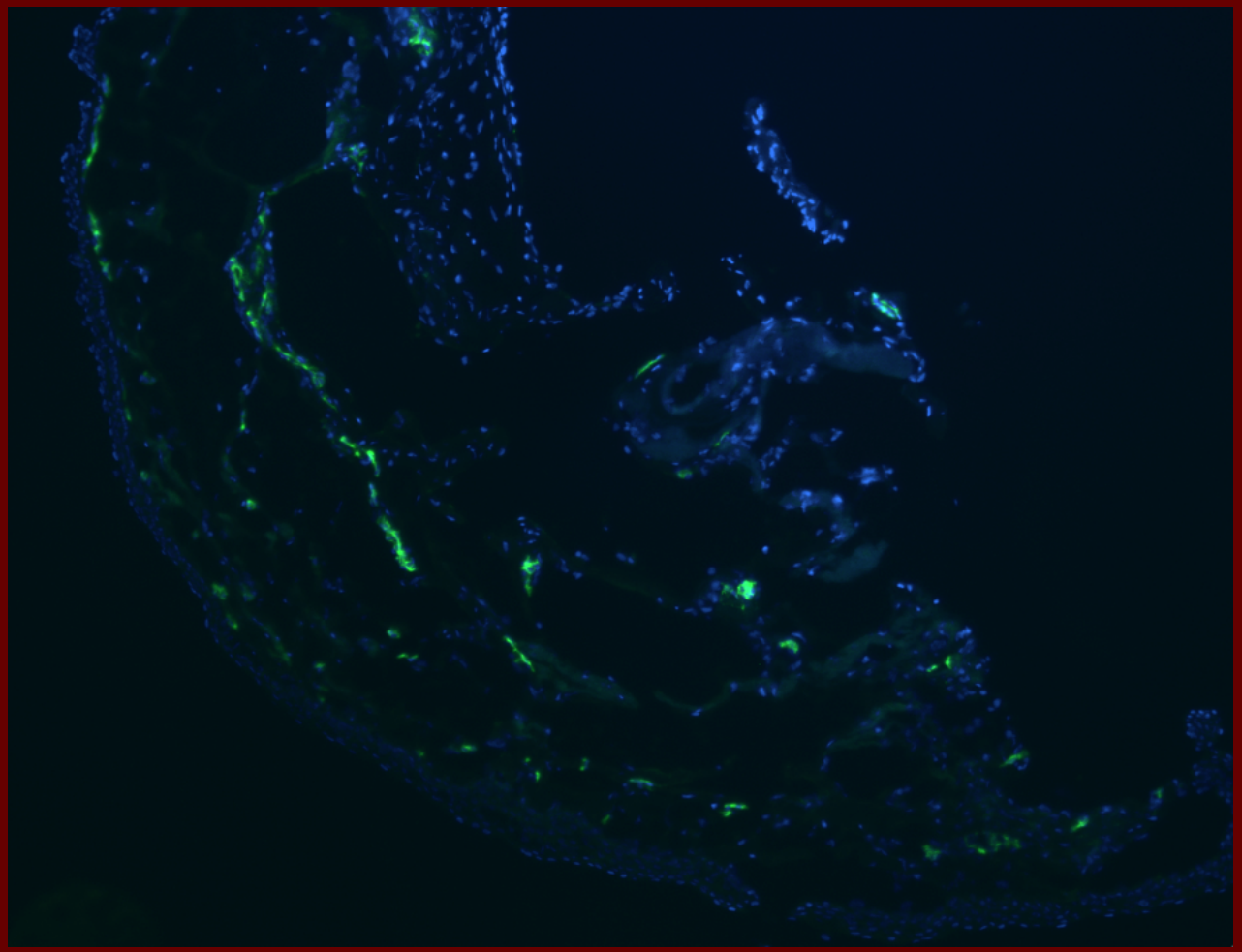

Results: Patient 1, CD31+

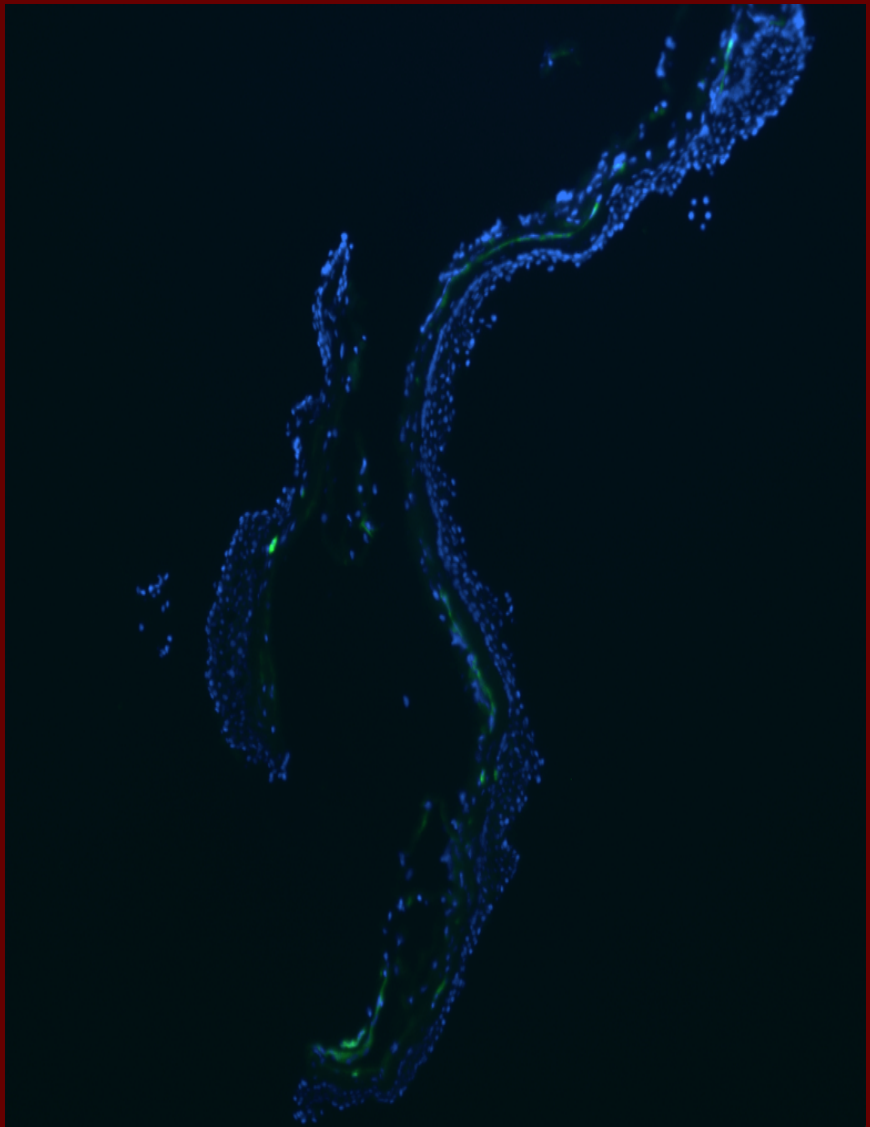

Results: Patient 1, VEGF+

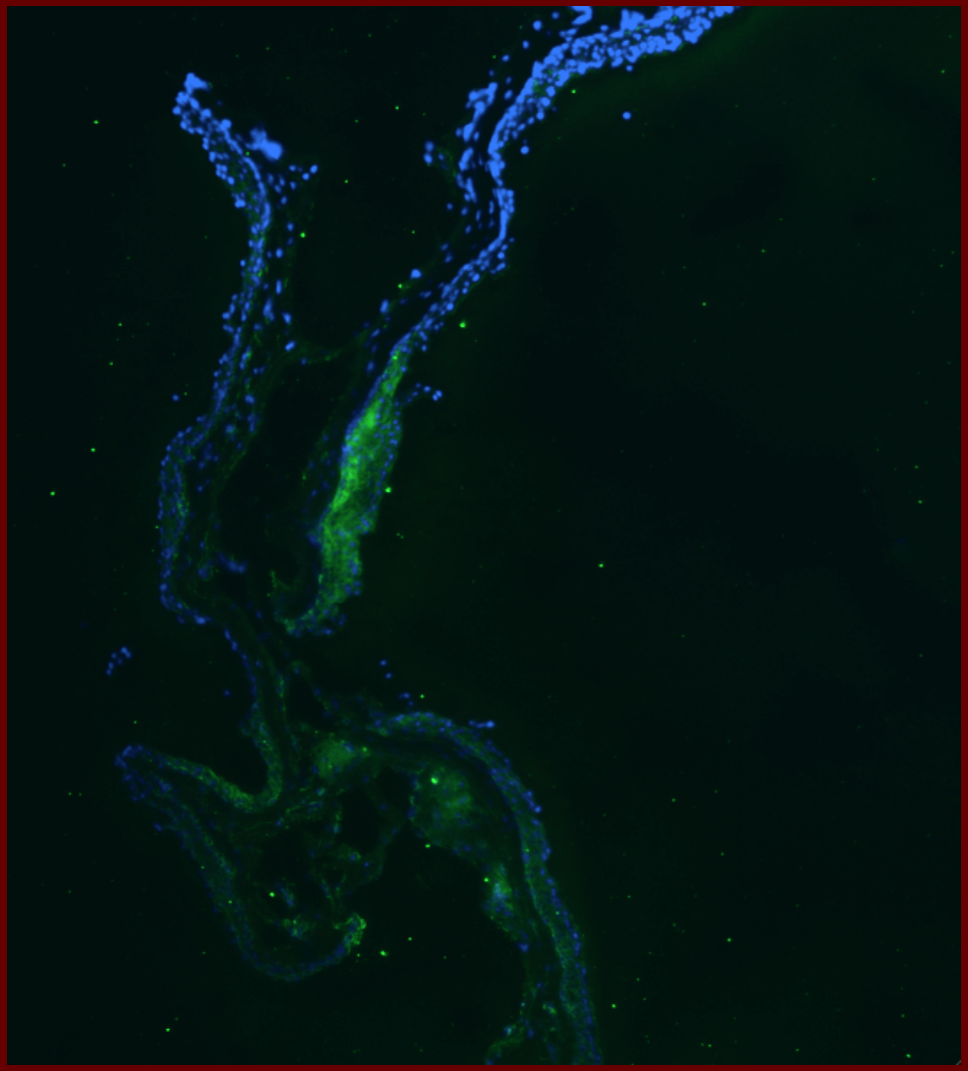

Doxycycline Magical Properties:

1. Anti-Angiogenic at low doses

2. Anti-bacterial at higher doses

Doxycycline's Effect on Ocular Angiogenesis: an *In Vivo* Analysis

Constance A. Cox,[1A] Juan Amaral,[1A] Rita Salloum,[1B] Liliana Guedez,[1B] Ted W. Reid,[2] Cindy Jaworski,[1A] Moly John-Aryankalayil,[1B] Ken A. Freedman,[2] Mercedes M. Campos,[1A] Alfredo Martinez,[1B] S. Patricia Becerra,[1A] and Deborah A. Carper[1A]

Author information ▶ Copyright and License information ▶

The publisher's final edited version of this article is available at Ophthalmology
See other articles in PMC that cite the published article.

Abstract

Go to

Purpose

To determine the *in vivo* effect of doxycycline (doxy) on choroidal angiogenesis and pterygium growth by using a choroidal neovascular murine model (CNV), a directed *in vivo* angiogenesis assay (DIVAA) and a pterygium murine model.

Design

Experimental Study

Participants

3 murine models were investigated with 4 mice minimum per group and 22 maximum per group.

Methods

Mice received water with or without doxycycline (Leiter's Pharmacy, San Jose, CA). For the CNV, the neovascular lesion volume was determined in choroid-retinal pigment epithelial (RPE) flat mounts using confocal microscopy seven days after laser induction. For DIVAA, silicone capsules containing 10,000 human pterygium epithelial cells were implanted in the flanks of mice subcutaneously. After eleven days neovascularization (NV) was quantified using spectrofluorimetry after murine tail-vein injection of fluorescein isothiocyanate (FITC)-labeled dextran. A pterygium epithelial cell model was developed by injecting 10,000 human pterygium epithelial cells in the nasal subconjunctival space in athymic nude mice. Doxy was started on day six at 50 mg/kg/day; corneal lesions that resulted from the injections were compared at days six and fifteen.

Main outcome measures

Student's *t-test* was used to evaluate the data for the CNV and DIVAA models and histologic preparations were used to evaluate pterygia lesions.

Results

There was significantly less NV and lesion volume with doxy taken in drinking water versus plain water. With doxy treatment, the laser-induced CNV showed a maximal 66% decrease in choroidal blood vessel volume ($p \leq 0.008$) and the DIVAA showed a 30% reduction of blood vessel growth and migration ($p < 0.004$). Histologic preparations demonstrated that pterygium cell lesions regressed when mice were administered doxy for 9 days.

Conclusions

Doxycycline significantly inhibited angiogenesis in three murine models. The most dramatic effect was found in the choroidal neovascularization model followed by the pterygia epithelial cell DIVAA model. The anterior segment pterygium model also showed regression histologically. This suggests that doxycycline may be successful as an adjunctive treatment for choroidal neovascularization and pterygia in humans; clinical trials would be necessary to determine if there is a benefit.

Central Theory of Rosacea by Sandra Lora Cremers, MD, FACS

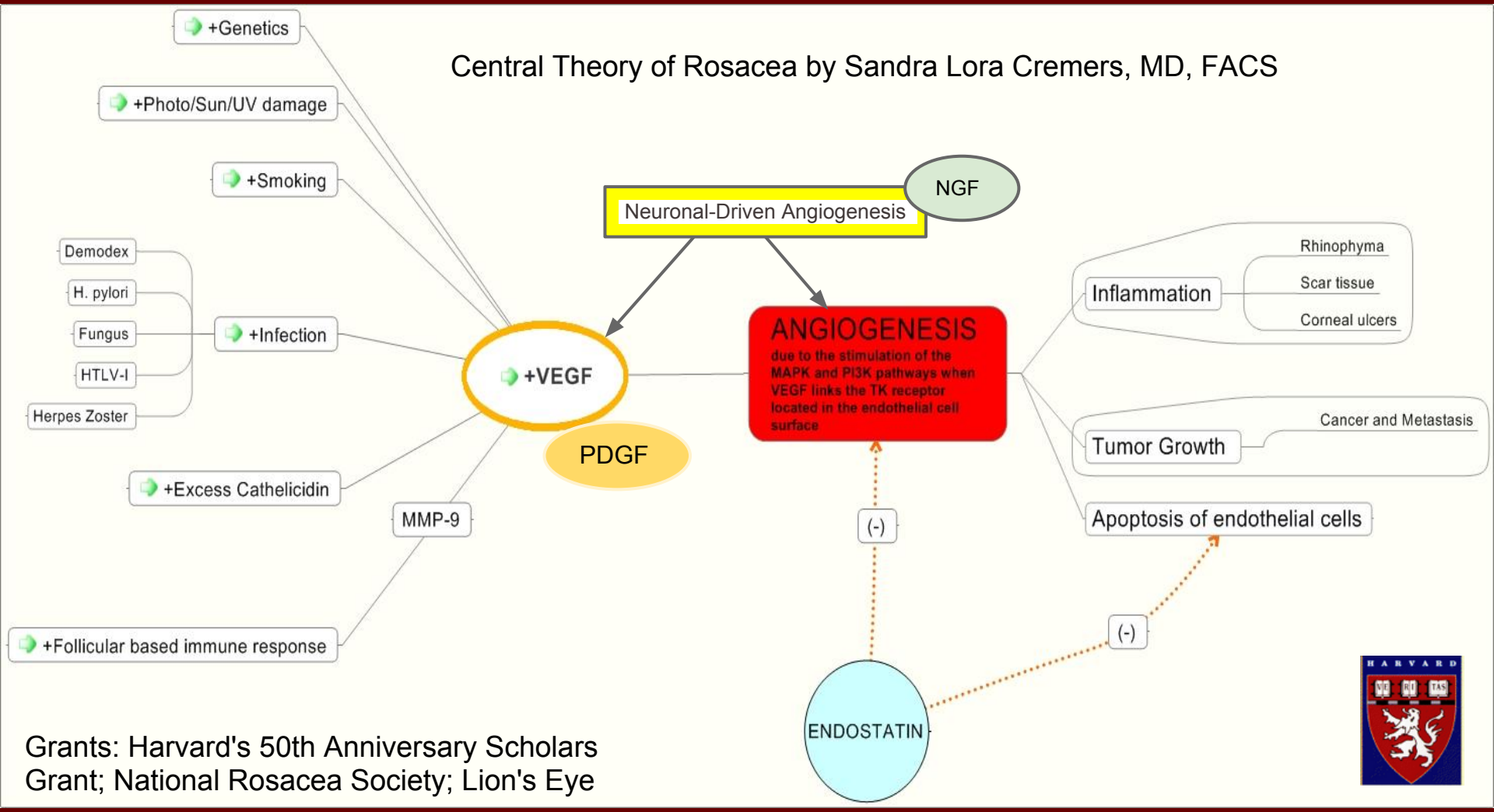

Grants: Harvard's 50th Anniversary Scholars Grant; National Rosacea Society; Lion's Eye

Central Theory of Rosacea by Sandra Lora Cremers, MD, FACS

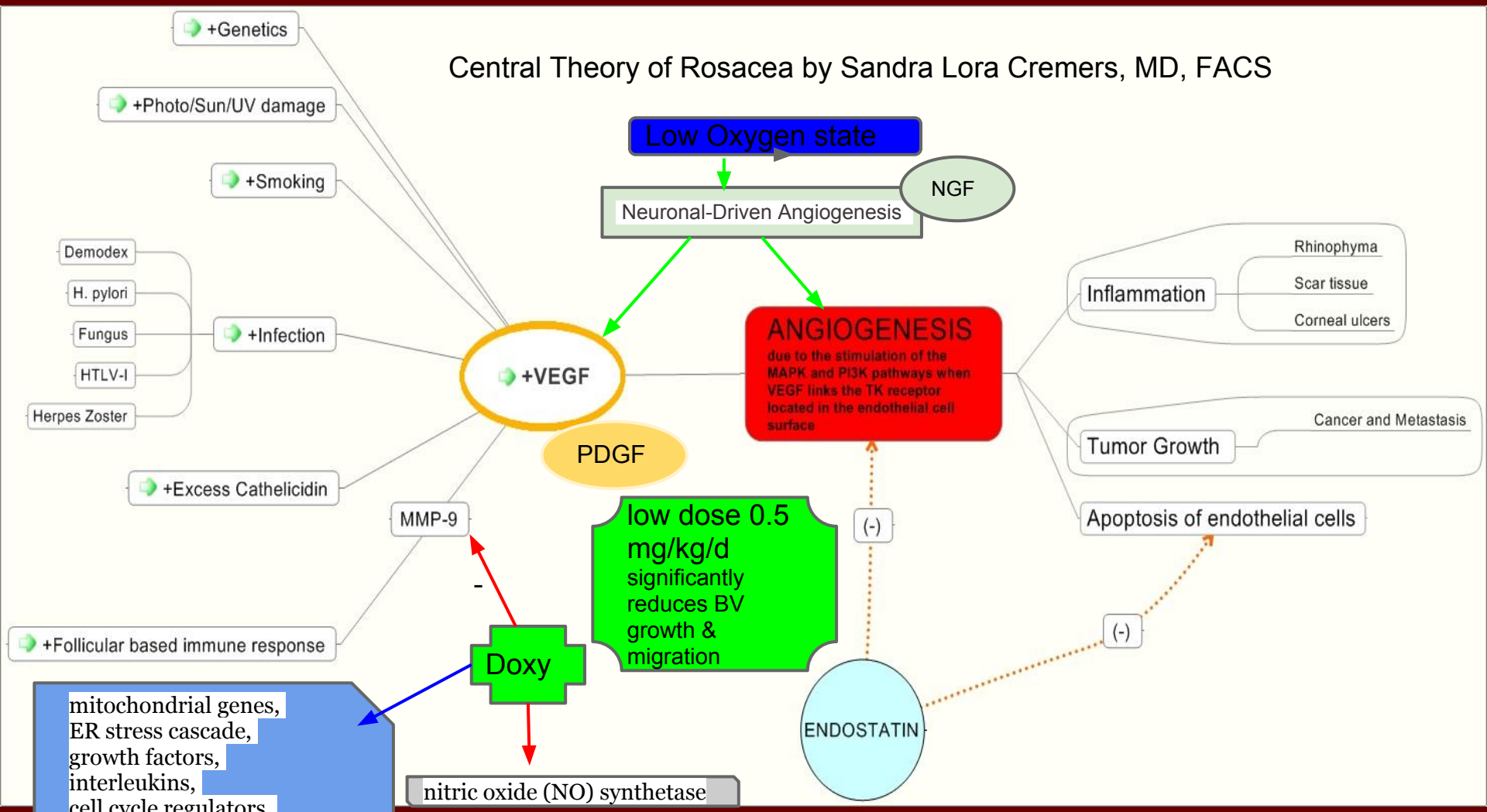

Grant provided by National Rosacea Society

More Complete Definition of Rosacea

Rosacea is a multifactorial, hyper-reactivity, vascular and neural based disease with a broad range of facial and ocular manifestations where normal vasodilation is greater and more persistent and involves an autoimmune component where microscopic amounts of extravasated plasma induce localized dermal and meibomian gland inflammation and where repeated external triggers lead to angiogenesis (the recruitment of new blood vessels), vasodilation, teleangiectasias, redness with eventual fibrosis and hypertrophic scarring of the dermis and meibomian glands.

Likely a central underlying factor in all subtypes of rosacea, particularly ocular rosacea, involves VEGF and similar angiogenic factors.

Future Research For Ocular Rosacea

1. Is Severe Ocular Rosacea due to increased angiogenesis activity at the lid margin?

2. Would they benefit from topical anti-angiogenic medications?

Future Research For Ocular Rosacea

1. Do severe ocular rosacea patients have an increased risk of systemic angiogenesis?

2. Do these patients need to be evaluated for an increased risk of internal tumors or metastasis if primary tumors present?

Recommendations for Ocular Rosacea Patients:

1. Avoid inflammatory factors (triggers, sun, smoke)

2. Eat antioxidants, Omega 3s,

2. If must treat with doxycycline, use lowest dose

Start with 20mg q day; 40-mg, controlled release formulation of doxycycline monohydrate is an anti-inflammatory drug

3. General medical check ups

Thank you for your attention.



References:

1. Rohrich RJ, Griffin JR, Adams WP., Jr Rhinophyma: Review and update. Plast Reconstr Surg.2002;110(3):860–869. quiz, 870.
2. Scheinfeld NS. Rosacea. Skinmed. 2006;5:191–194.

3. Glycomic analysis of tear and saliva in ocular rosacea patients: the search for a biomarker. Ocul Surf. 2012 Jul;10(3):184-92 , Vieira AC, An HJ, Ozcan S, Kim JH, Lebrilla CB, Mannis MJ.

2. http://rosacea-support.org/ocular-rosacea-diagnostic-test-one-step-closer.html

3.

4. Perry HD, Doshi-Carnevale S, Donnenfeld ED, et al. Efficacy of commercially available topical cyclosporine A 0.05%

in the treatment of meibomian gland dysfunction. Cornea. 2006;25:171-175

3. Stone, Curr Opin Ophthalmol, 2004

http://www.rosacea-treatment.org/

6. http://videos.med.wisc.edu/videos/37571
7. Doxycycline's Effect on Ocular Angiogenesis: an In Vivo Analysis.

Ophthalmology 2010 Sept, 117(9): 1782-1791. Cox, C, et al.

8. http://www.ncbi.nlm.nih.gov/pmc/articles/PMC3315879/

9. Del Rosso JQ, Bikowski JB. Multicenter, doubleblind, randomized, placebo-

References continued:

9. Del Rosso JQ, Bikowski JB. Multicenter, doubleblind, randomized, placebo-controlled, parallelgroup trial results evaluating the effects of 40 mg doxycycline monohydrate controlled-release capsules in the treatment of rosacea. Poster presented at: 64 th American Academy of Dermatology Meeting ; March 3–7, 2006; San Francisco, Calif.
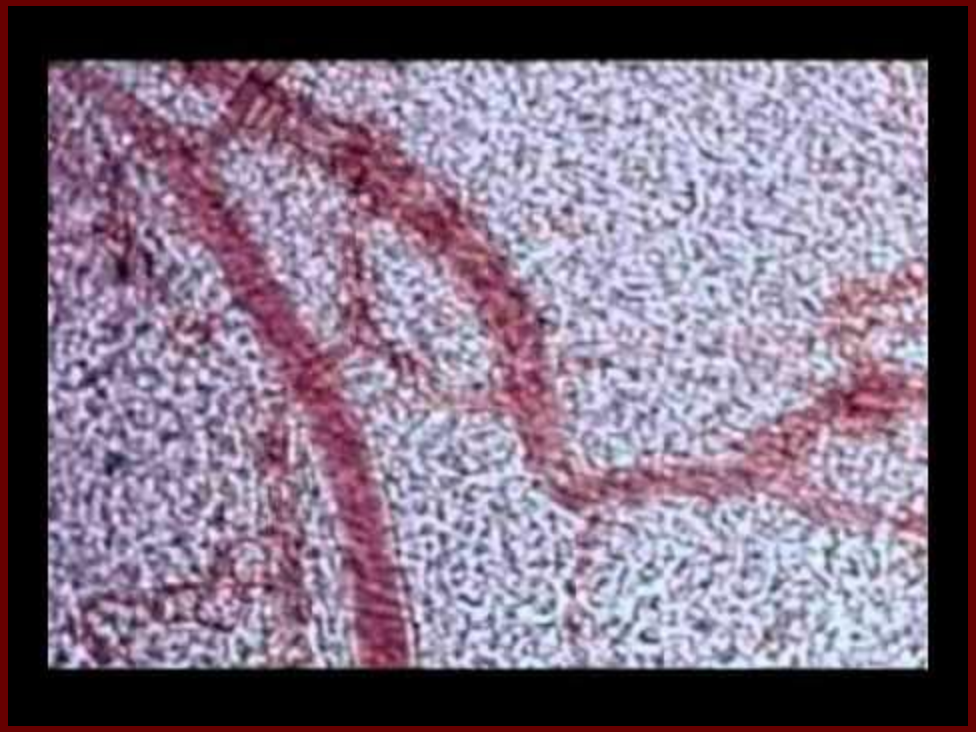
10.http://www.globalacademycme.com/fileadmin/pdf/supplement_pdf/fczjw6vm_sanews_supplement46.pdf